


# DRESSING AND BANDAGES



**WHAT YOU NEED TO KNOW...**

**A DRESSING IS A PIECE OF  
STERILE CLOTH THAT COVERS  
A WOUND TO PREVENT  
INFECTION AND/OR TO STOP  
BLEEDING.**



# **WHAT YOU NEED TO KNOW...**

- **WASH HANDS AND WEAR GLOVES IF POSSIBLE**
- **PLACE THE DRESSING OVER THE WOUND**
- **IF THE BODY TISSUE OR ORGAN ARE EXPOSED, COVER THE WOUND WITH DRESSING THAT WILL STICK**
- **SECURE THE DRESSING WITH A BANDAGE OR ADHESIVE TAPE**

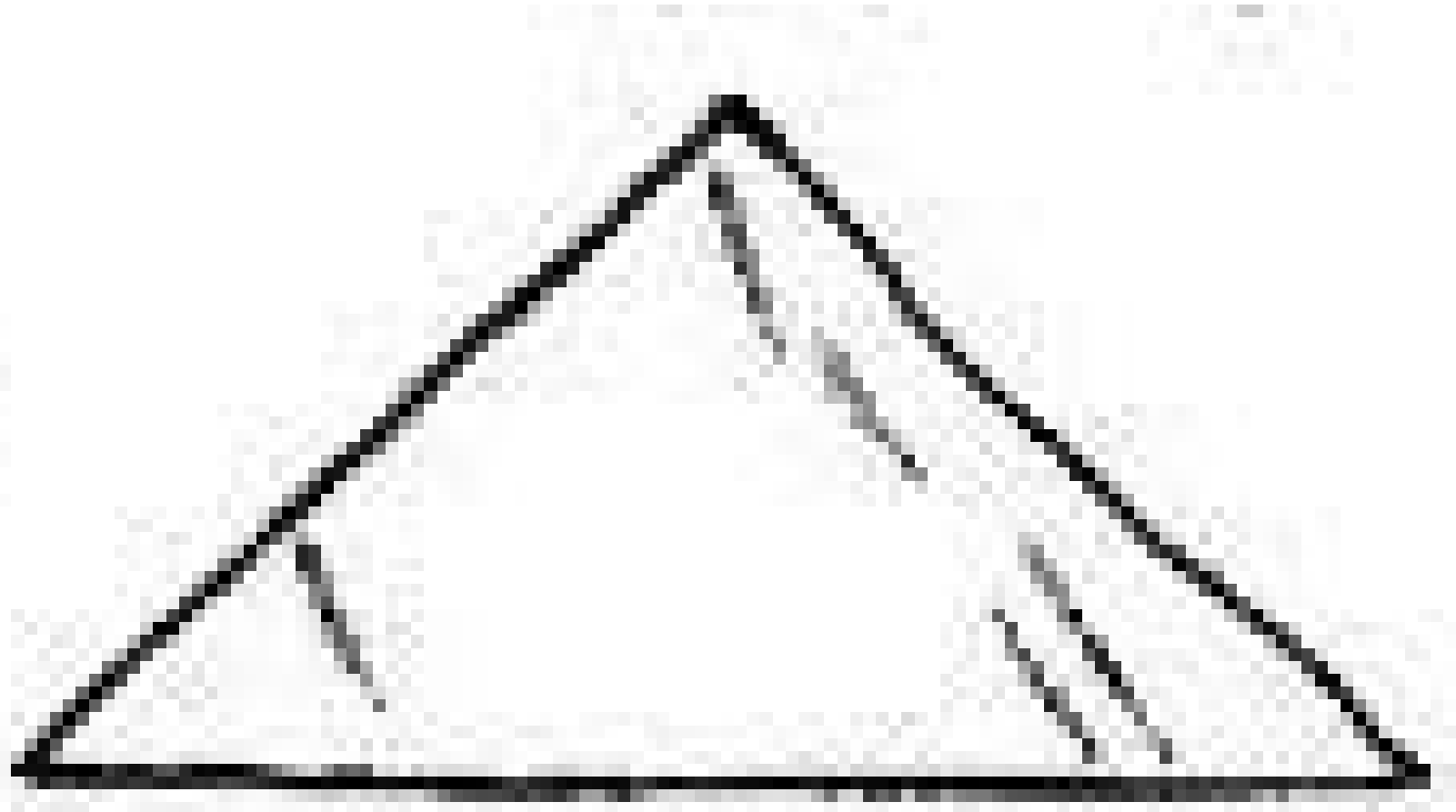

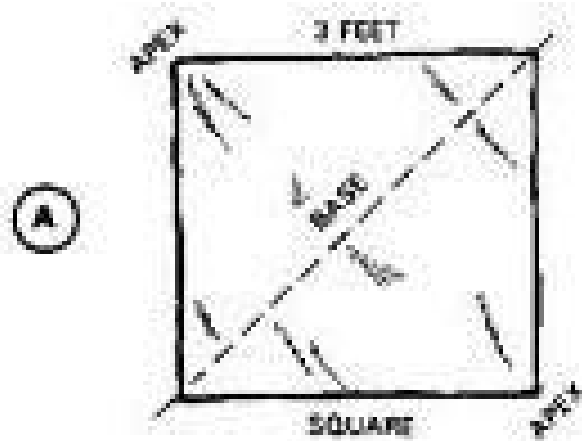


# TWO PHASE OF BANDAGING

- **OPEN PHASE** (for wounds on the top and back of the head, chest, back, hand and foot, and as arm sling)
- **CRAVAT PHASE** (wounds that need extra support like wound on eye, forehead, ear, cheek, jaw, shoulder, hip, arm, leg, elbow, knee and palm and for a sprained ankle)



# TWO PHASE OF BANDAGING




**OPEN PHASE**

**TRIANGULAR BANDAGE**



# TWO PHASE OF BANDAGING

C



CRAVAT (ONE FOLD)

D



CRAVAT (TWO FOLDS)

E



CRAVAT (THREE FOLDS)



CRAVAT (ONE FOLD)



CRAVAT (TWO FOLDS)

**CRAVAT PHASE**

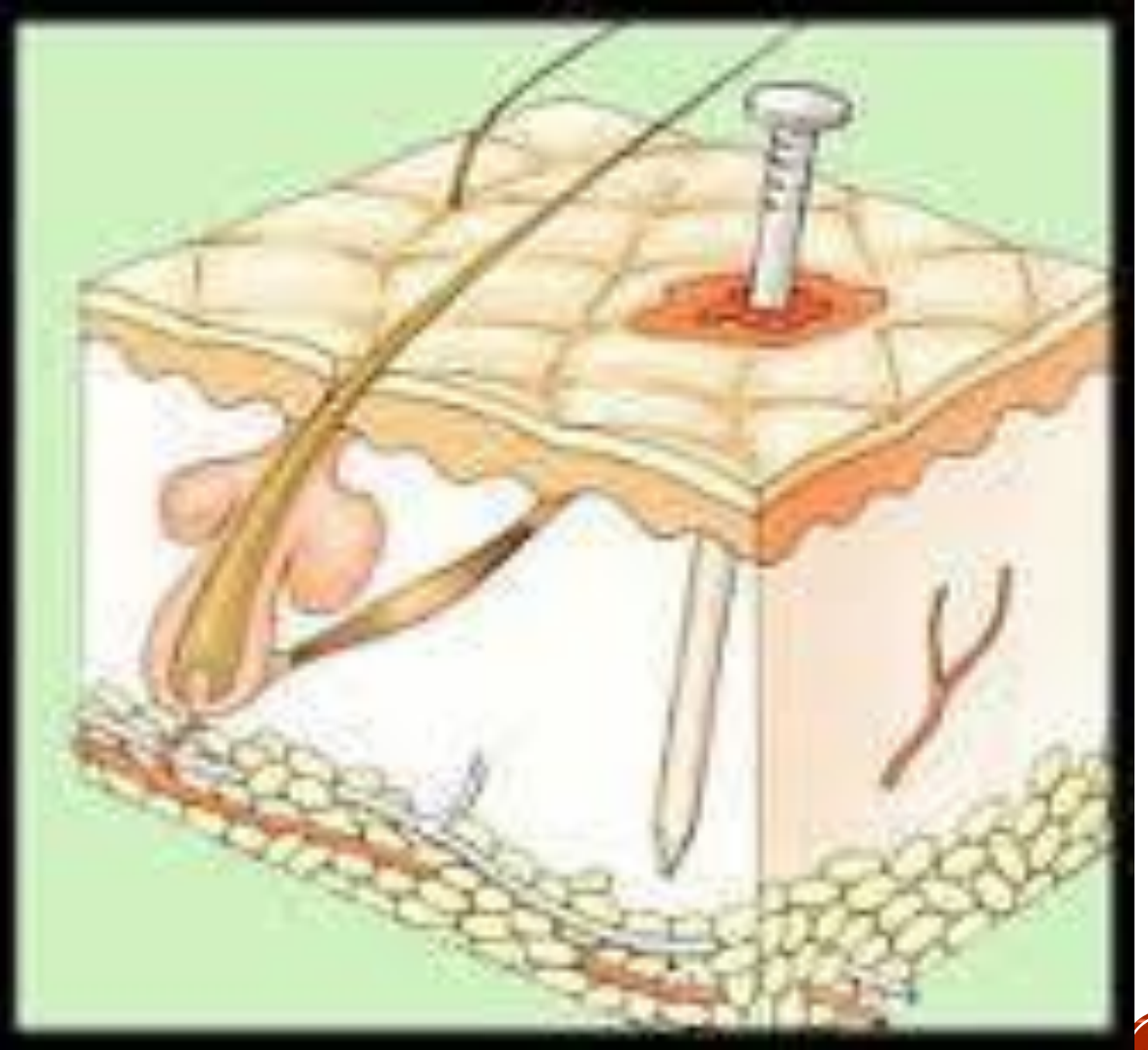
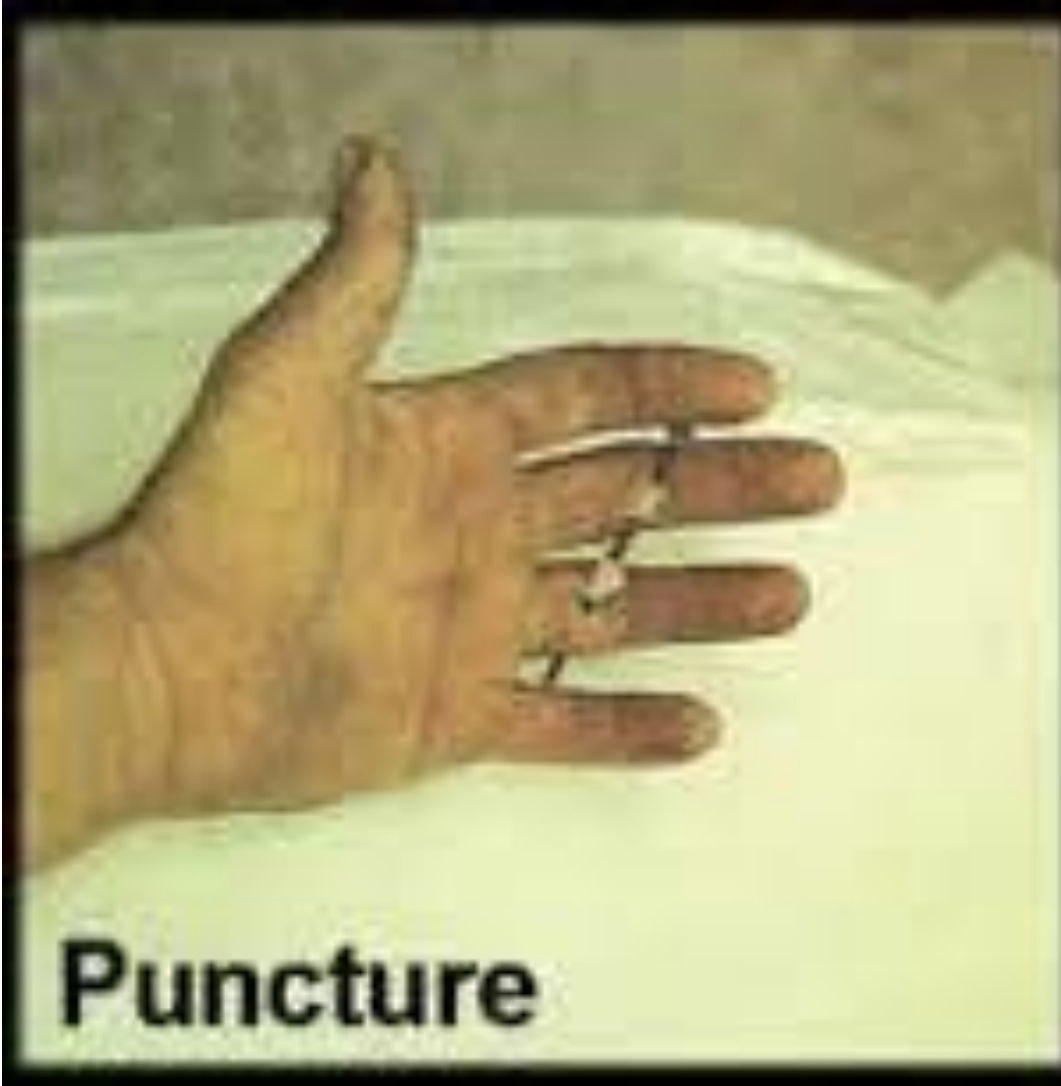

# WOUNDS

- A WOUND IS A BREAK IN THE CONTINUITY OF TISSUE IN THE BODY. (CLOSED WOUND - HEMATOMA, OPEN WOUND - BREAK WITH THE SKIN)



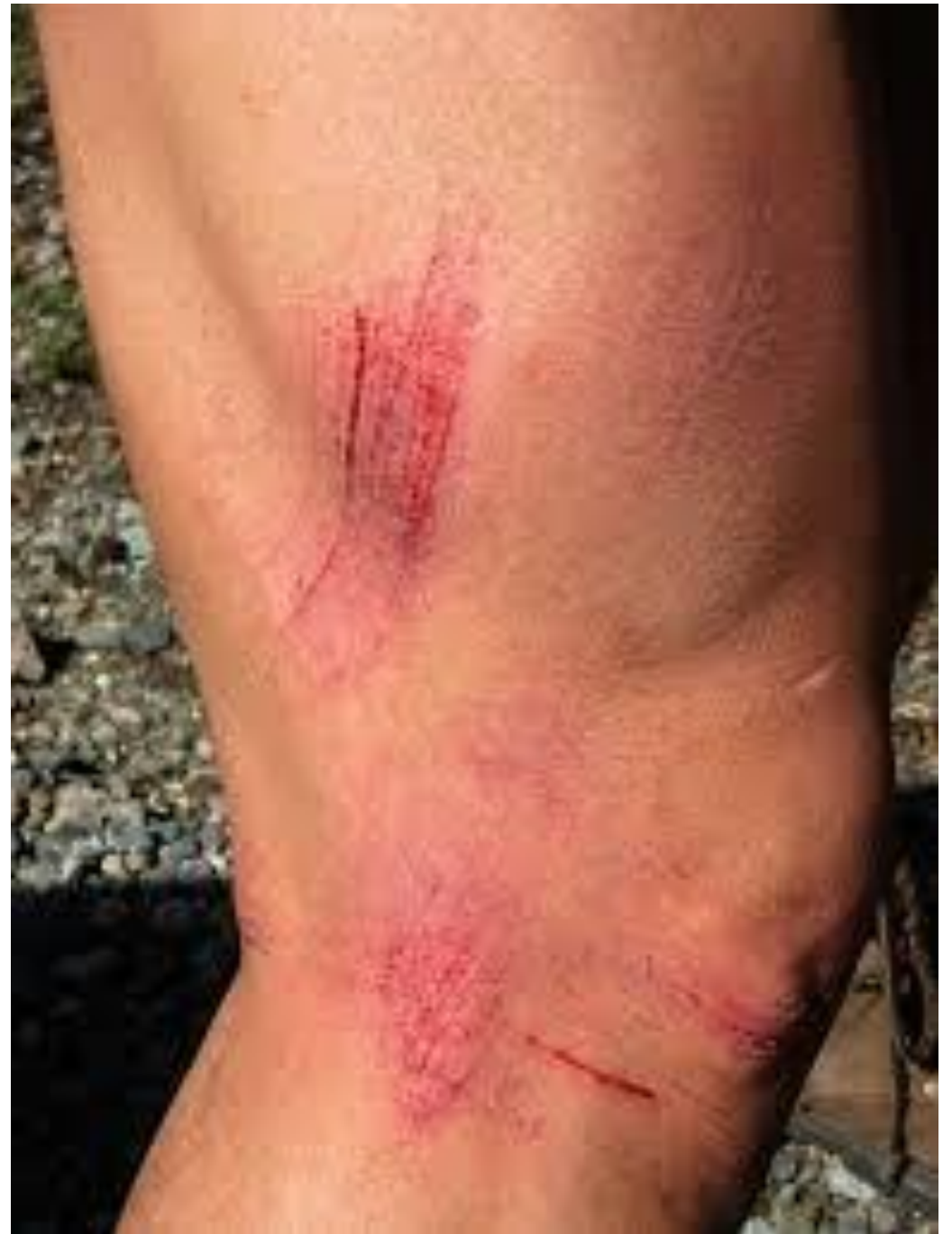# KINDS OF OPEN WOUNDS





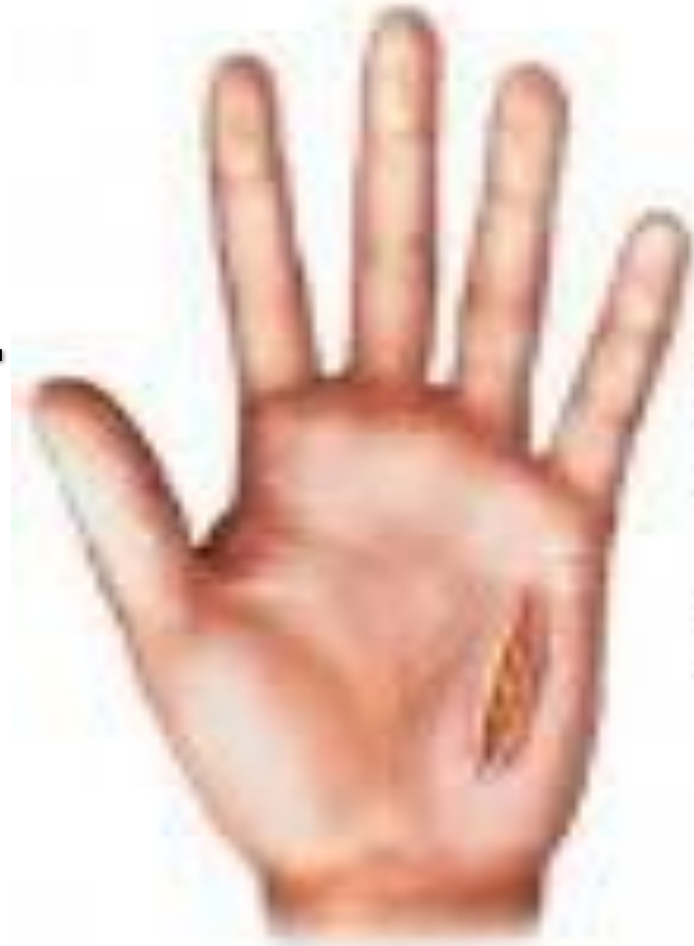# KINDS OF OPEN WOUNDS

## Abrasion

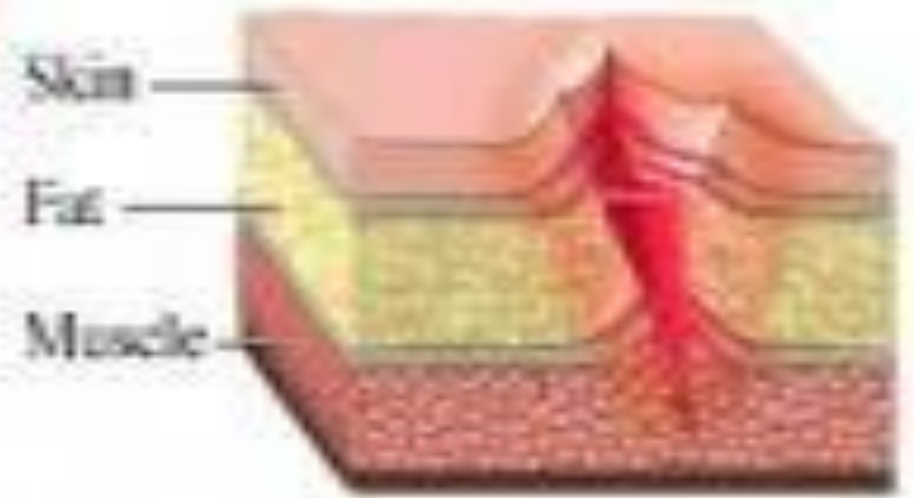


# KINDS OF OPEN WOUNDS

## Laceration



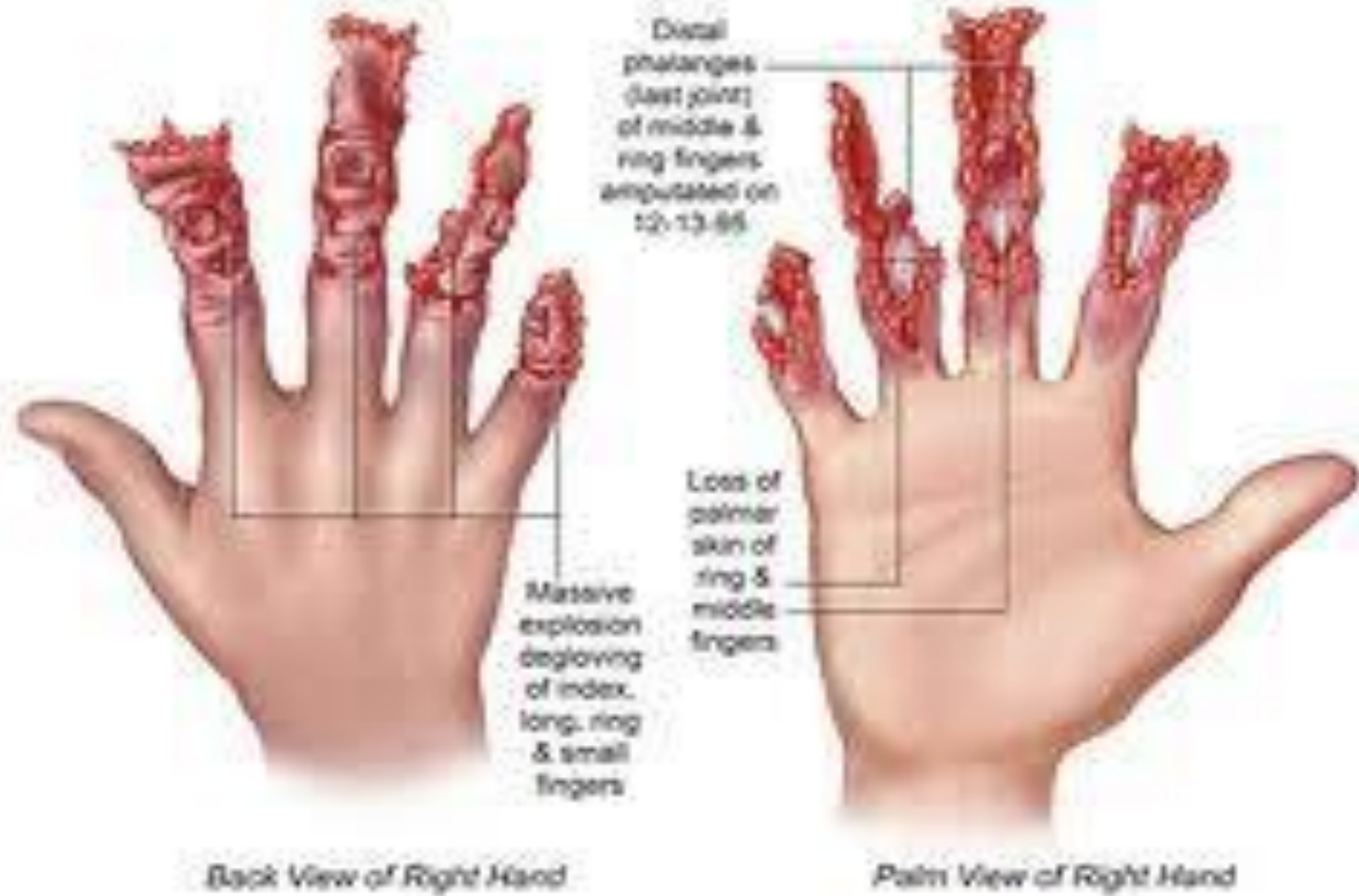Deep laceration wound



# KINDS OF OPEN WOUNDS

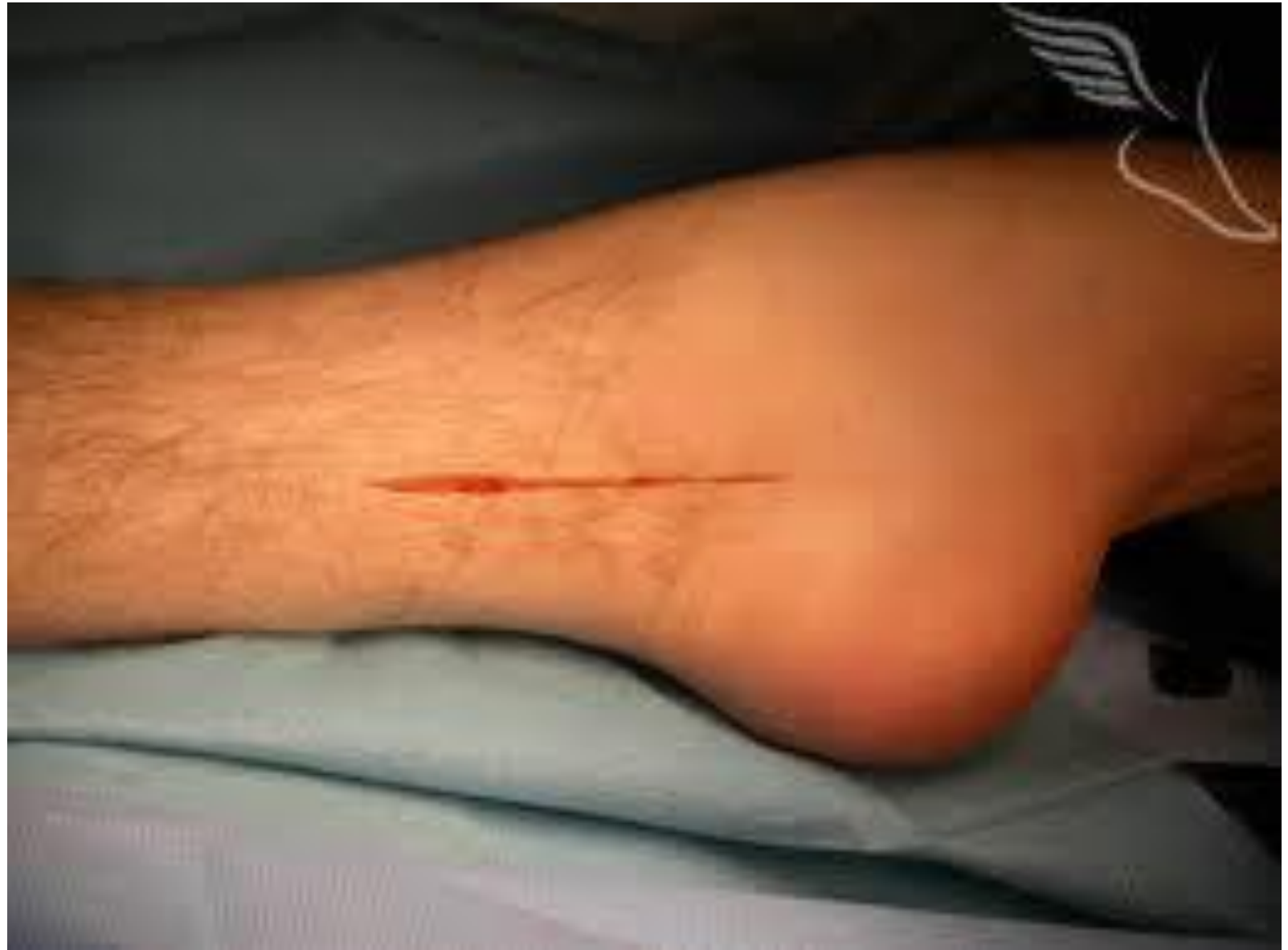Aaron P's Roller Crush Avulsion Injury of 12-9-95

## Avulsion



# KINDS OF OPEN WOUNDS

## Incision

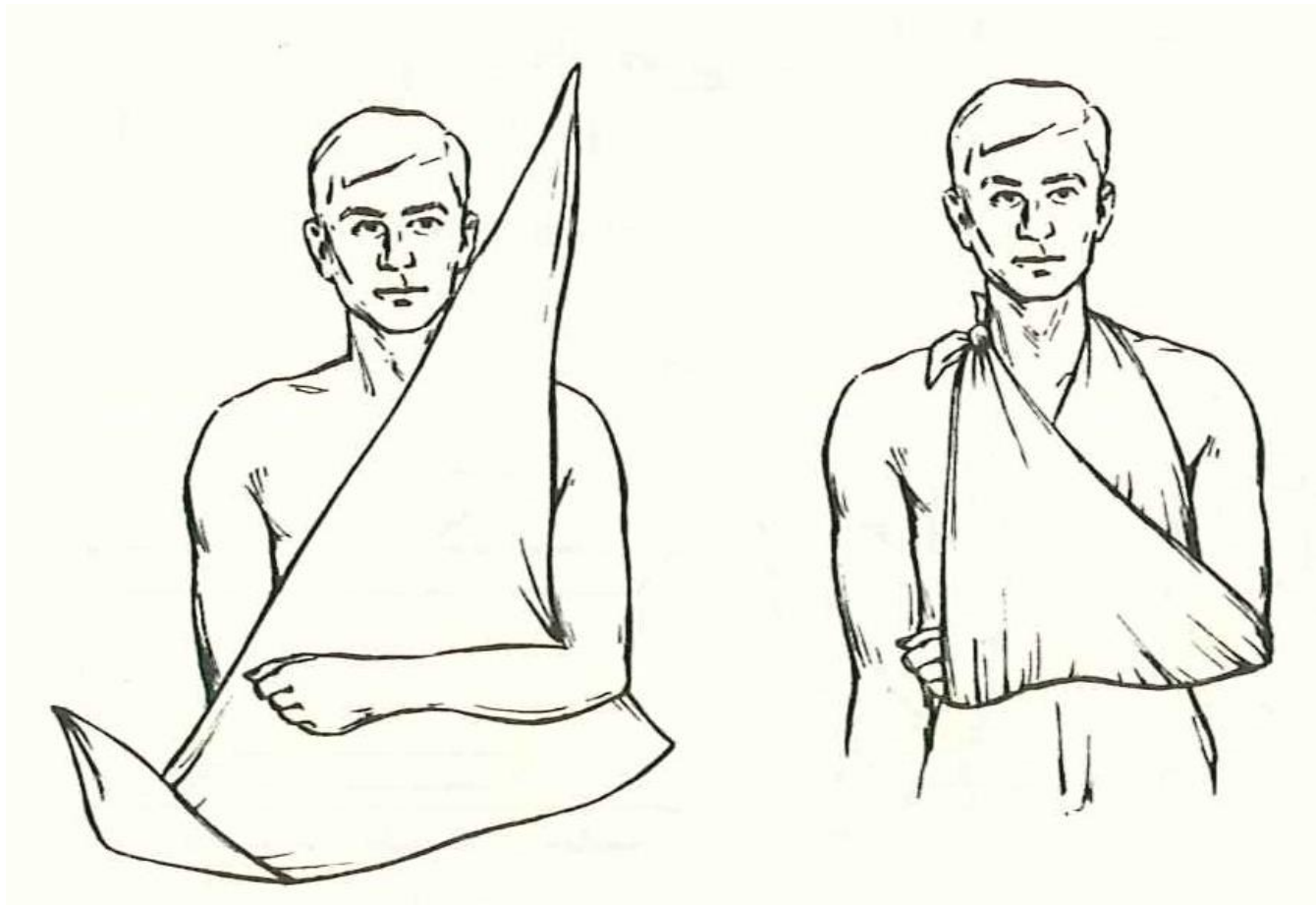


# **TECHNIQUES IN BANDAGING**

- **ALWAYS USE A SQUARE KNOT**
- **KEEP THE CLOTH STERILE TO AVOID INFECTION**
- **ALWAYS KEEP THE ENDS**



# TECHNIQUES IN BANDAGING

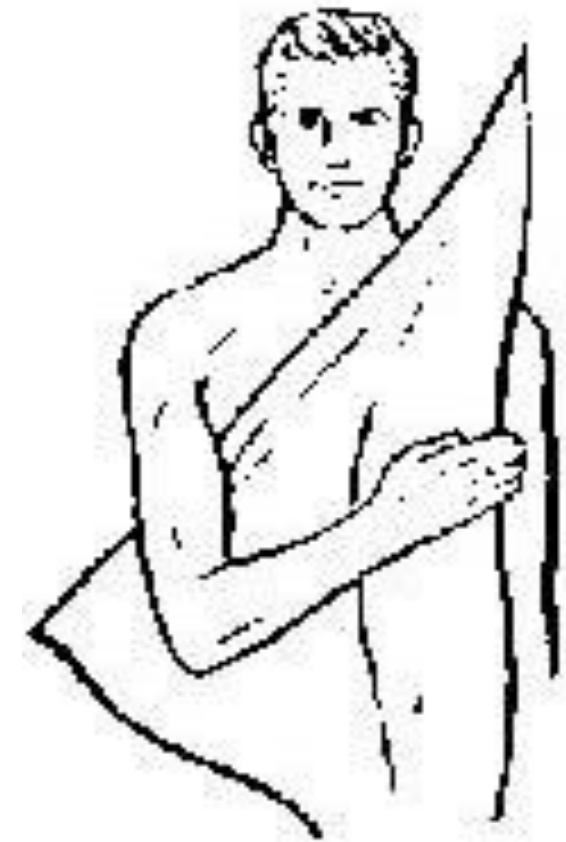


**Arm sling**

## TRIANGLES & CRAVATS - INDEX ②



# TECHNIQUES IN BANDAGING



Under arm sling



# TECHNIQUES IN BANDAGING

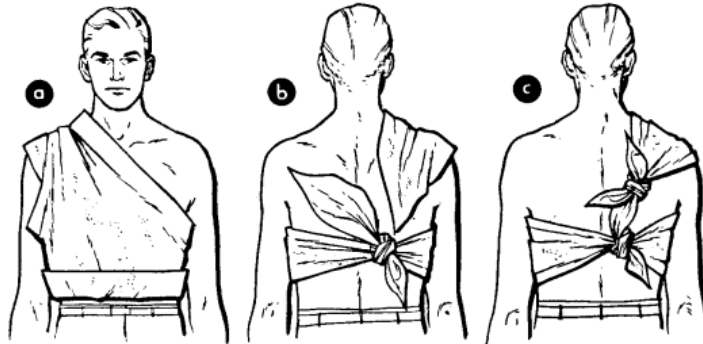
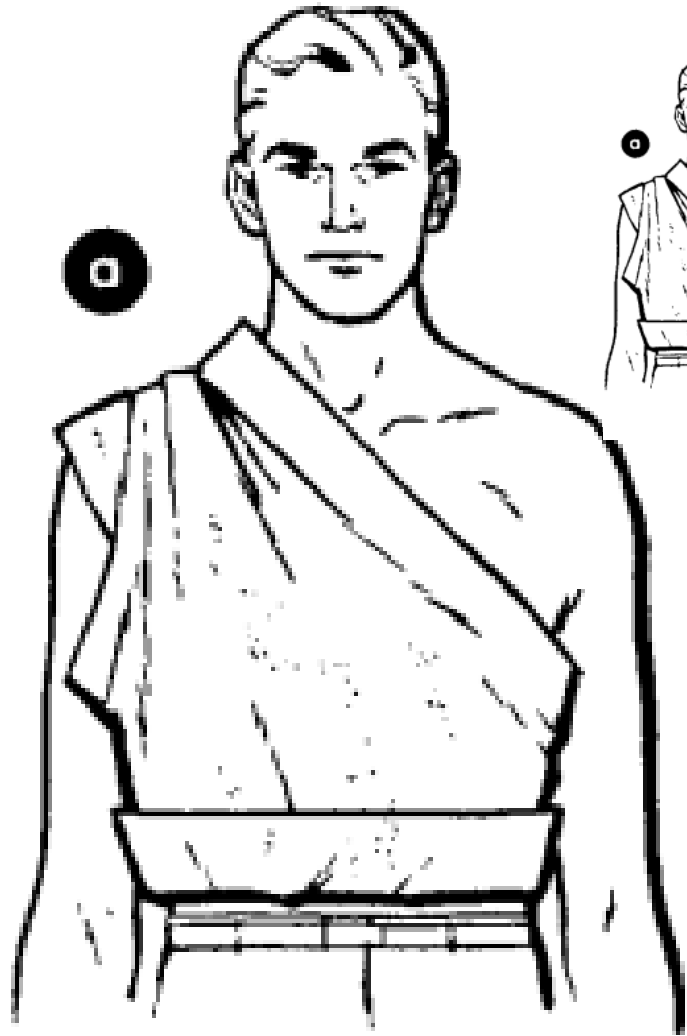


Figure 5. Triangle of chest or back.

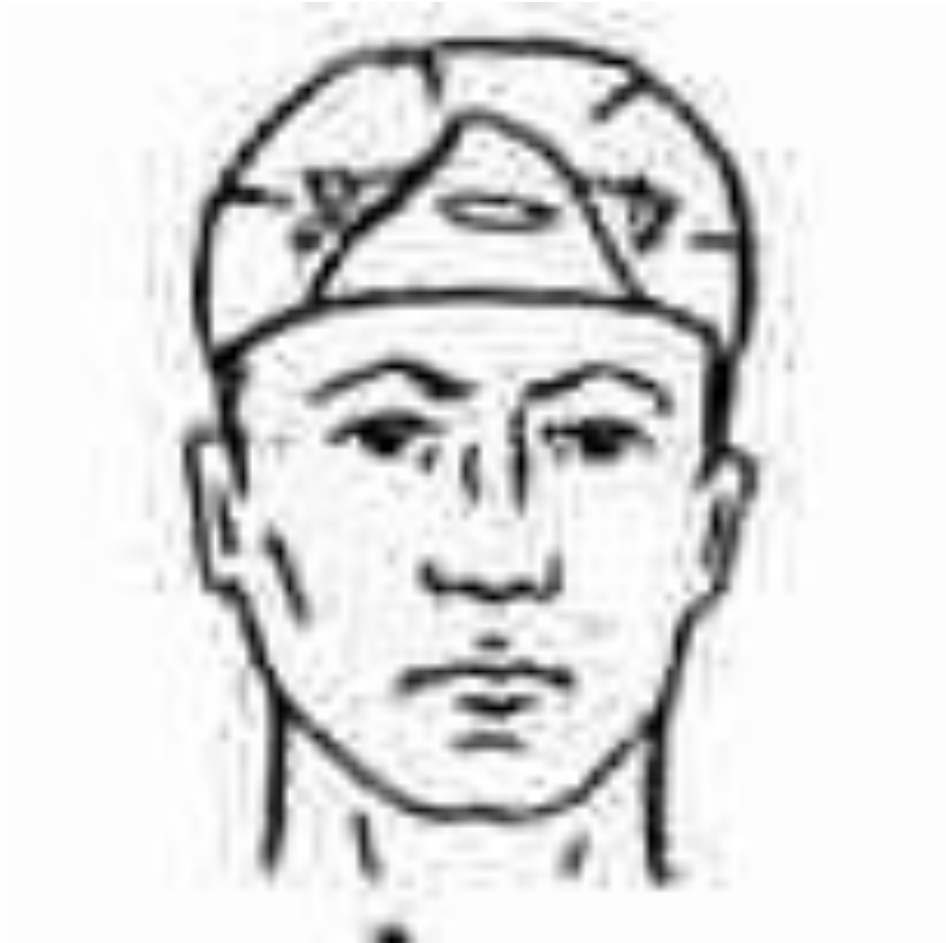Triangle of chest or back

## TRIANGLES & CRAVATS - INDEX ②





# TECHNIQUES IN BANDAGING



Top of the head



# TECHNIQUES IN BANDAGING

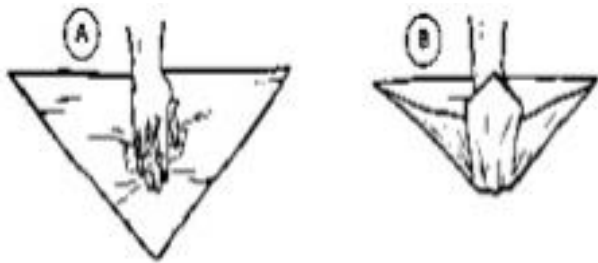


Figure 3-38. Triangular bandage applied to hand (Illustrated A thru E).

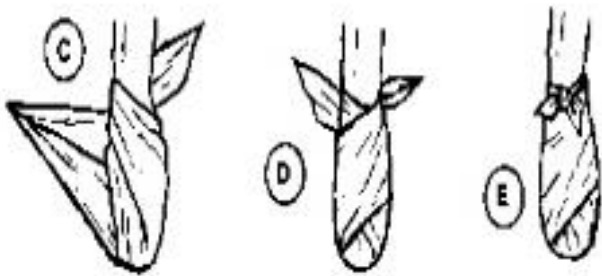


Figure 3-38. Continued.

## Hand (burn)

### TRIANGLES & CRAVATS - INDEX ②



# TECHNIQUES IN BANDAGING

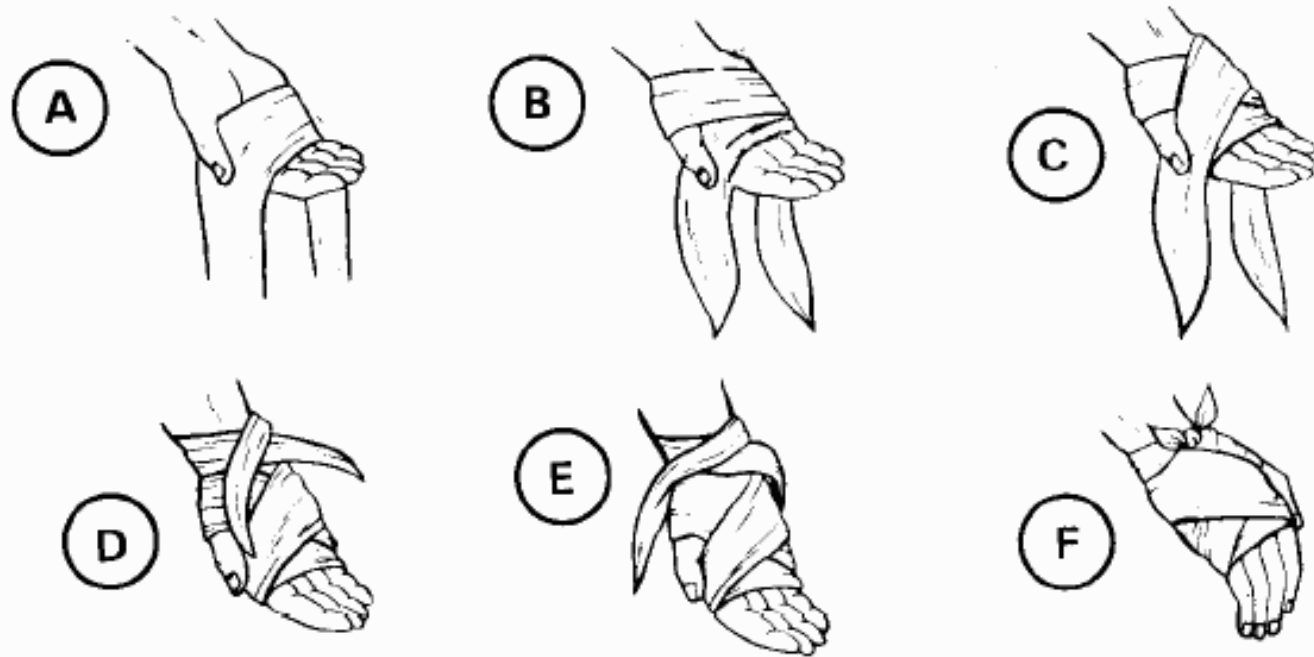


Figure 3-39. Cravat bandage applied to palm of hand (Illustrated A thru F).

## Open palm (cut)



# TECHNIQUES IN BANDAGING


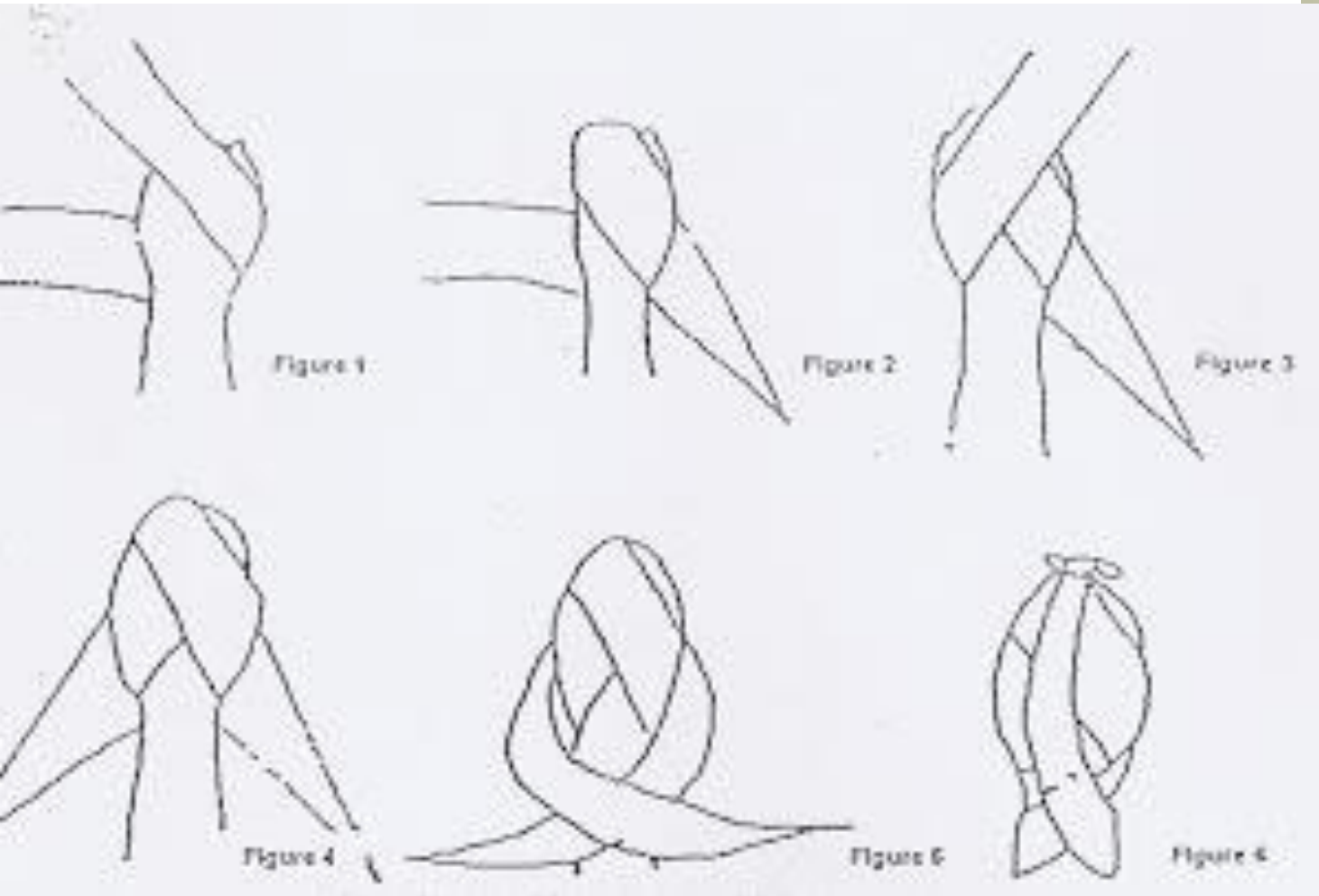


Figure 4-28. Fractured jaw immobilized illustrated A thru C.

Jaw, ear, cheek



# TECHNIQUES IN BANDAGING



**Closed palm (cut)**

## TRIANGLES & CRAVATS - INDEX ②



# TECHNIQUES IN BANDAGING

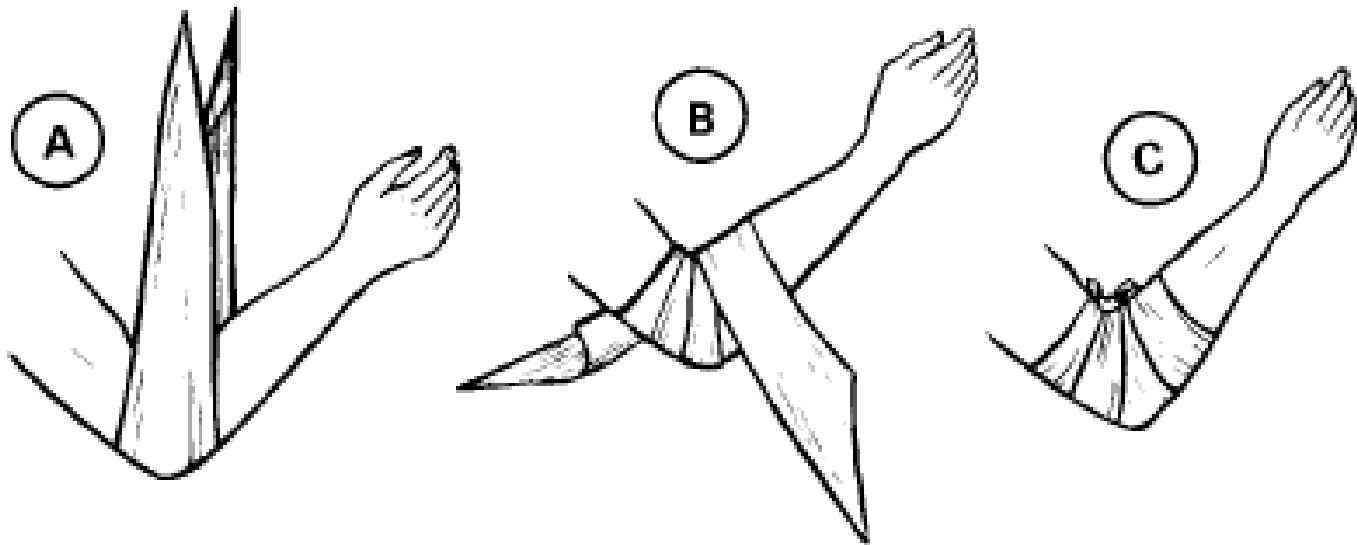


Figure 3-37. Elbow bandage (Illustrated A thru C).

## Elbow



# TECHNIQUES IN BANDAGING

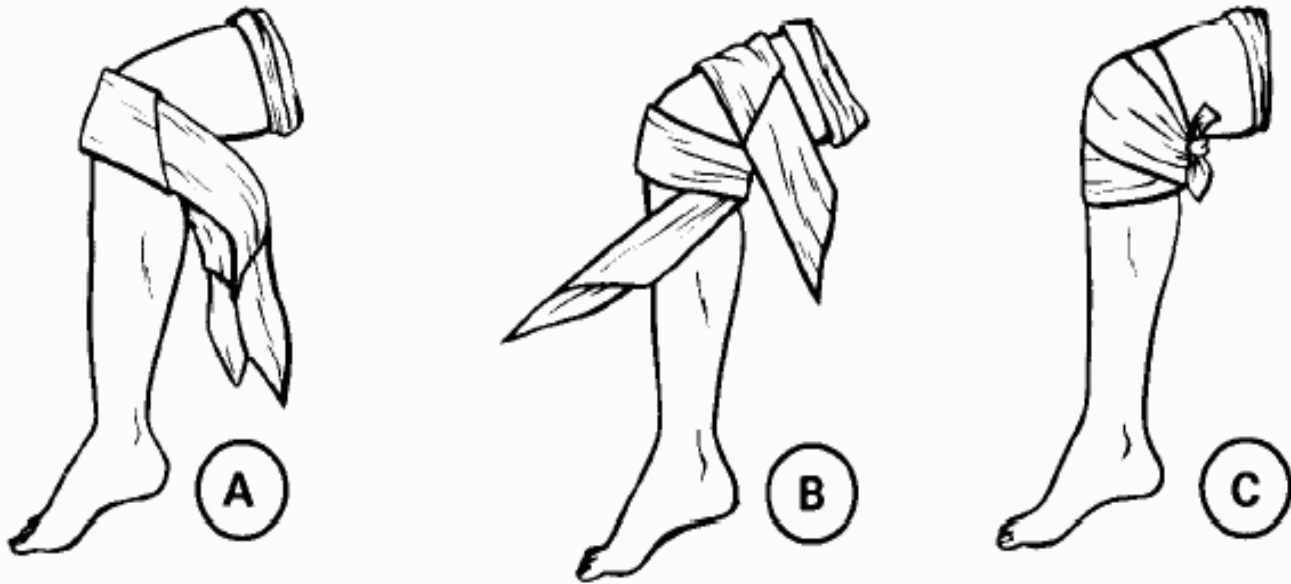


Figure 3-41. Cravat bandage applied to knee (Illustrated A thru C)

## Knee

